

LETTERS TO THE EDITOR

Efficacy of single dot ultrasound combined with radiofrequency for low eyelid laxity

To the editor

Aging of the lower eyelid is a major cosmetic concern and noninvasive correction of skin laxity have long been elusive goals of aesthetic surgery. Various non-ablative skin resurfacing techniques such as high-intensity focused ultrasound (HIFU) and radiofrequency (RF) have been designed to selectively induce thermal injury within the dermis while sparing the overlying epidermis.^{1,2} They have been used successfully for lifting eyebrows, nasolabial folds, and jaw tightening. However, as the linear irradiated energy has a large area in contact with the skin, there has been a limit to the treatment around the eyes and curved areas.^{3,4}

Recently, a newly developed lifting HIFU device that combines RF technology in one flat handpiece with a diameter of 2.5 cm was introduced. The ultrasound energy is irradiated in the single dot form rather than a line composed of dots and therefore it is expected to optimize to treat delicate areas such as the area around the eyes (Figure 1). In this case report, we report the clinical effectiveness of single dot HIFU combined with RF for the improvement of low eyelid laxity.

A 53-year-old female patient visited with a complaint of low eyelid laxity (Figure 2A). The HIFU combined bipolar RF device (V-RO, Hironic Corp.) applied on periorbital area and mid face with parameters of a 3.0 mm depth, 0.5 J power, 4.0 RF level, 5 Hz after obtaining written informed consent. Topical anesthetics was applied on the treatment area 30 min prior to the procedure. For the eye protection, eye shield was inserted. Total 300 shots per session were irradiated.

Immediately after irradiation, the treated area was cooled with ice packs; no prophylactic antibiotics were prescribed. Photograph was taken and evaluated by non-treating dermatologist and the efficacy point was clinical improvement in the tightening of infraorbital laxity at 1 month after one session treatment compared to the initial photograph using grading scale (0, worse; 1 no change; 2, improved; 3, much improved). One month after the single treatment, there was an improvement (score = 2) in eyelid laxity (Figure 2B). No notable side effect was reported. Another 55-year-old female patient presenting with low eyelid laxity (Figure 2C) received two sessions of the treatment with 2 weeks of interval after obtaining informed consent. Total 300 shots per session with parameters of a 3.0 mm depth, 0.5 J power, 4.0 RF level, 5 Hz were irradiated. One month after the last session, much improvement (score = 3) in skin laxity was noted (Figure 2D).

In this report, we demonstrated improvements in infraorbital laxity which was achieved using single dot ultrasound combined with RF. The device produces the energy in the single dot form rather than a line composed of dots and therefore offers to treat delicate areas such as the area around the eyes. This provided advantages of minimizing side effects and enabling precise treatment for the low eyelid laxity. Another advantage of the device include the synergy dotting handpiece in which HIFU and RF are combined in one handpiece. Both HIFU and RF causes a contraction of the deep dermal layer and superficial muscular aponeurotic system (SMAS) and remodeling of the targeted collagen fibers, resulting in significant skin

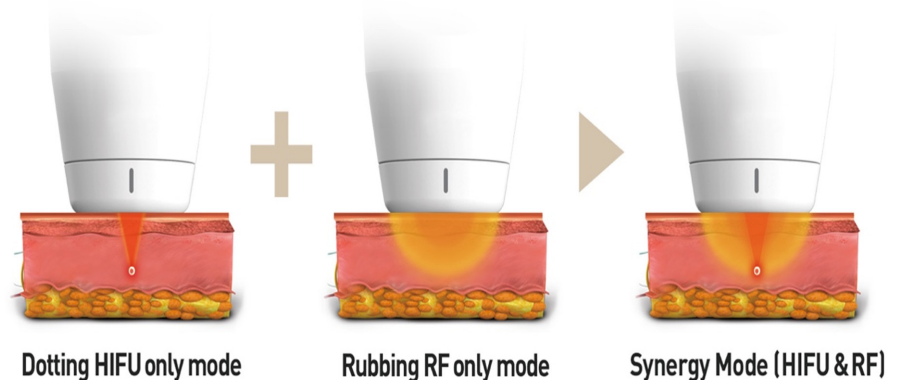


FIGURE 1 Scheme of synergy effect in single dot high-intensity focused ultrasound (HIFU) and radiofrequency (RF).

This is an open access article under the terms of the [Creative Commons Attribution](https://creativecommons.org/licenses/by/4.0/) License, which permits use, distribution and reproduction in any medium, provided the original work is properly cited.

© 2023 The Authors. *Journal of Cosmetic Dermatology* published by Wiley Periodicals LLC.

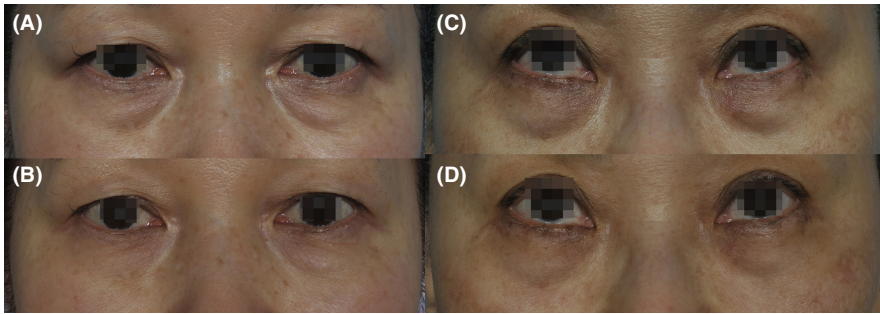


FIGURE 2 (A) Case 1: Before treatment, (B) 1 month after one session of treatment, there was an improvement in low eyelid laxity of 53-year-old female. (C) Case 2: Before treatment, (D) 1 month after two sessions of treatment, there was much improvement in eyelid laxity in 55-year-old female.

tightening and lifting.³ Histological analyses has revealed that RF delivery is more diffuse, whereas HIFU is sharply focused, suggesting combining these two devices, simultaneously or sequentially, may exert synergistic tightening effects by compensating for the different effects in each skin layer.⁵ Indeed, in this case we could observe improvement of infraorbital laxity with only one session treatment.

Our limitation is the short interval of follow-up, 2 months, and not to perform a quantitative analysis to measure laxity with objective devices.

Taken together, these cases demonstrated the effectiveness of single dot ultrasound combined with RF for low eyelid laxity.

ACKNOWLEDGMENTS

This work was supported by Hironic Co.

FUNDING INFORMATION

HIRONIC

DATA AVAILABILITY STATEMENT

The data that support the findings of this study are available from the corresponding author upon reasonable request.

Jiehoon Kim MD

Soeun Jung MD

Dr. Kim's Skin & Laser Clinic, Suwon, Korea

Correspondence

Jiehoon Kim, Dr. Kim's Skin & Laser Clinic, Suwon, Korea.

Email: jiehoon@naver.com

REFERENCES

1. Greene RM, Green JB. Skin tightening technologies. *Facial Plast Surg.* 2014;30:62-67.
2. Lolis MS, Goldberg DJ. Radiofrequency in cosmetic dermatology: a review. *Dermatol Surg.* 2012;38:1765-1776.
3. Suh DH, Shin MK, Lee SJ, et al. Intense focused ultrasound tightening in Asian skin: clinical and pathologic results. *Dermatol Surg.* 2011;37:1595-1602.
4. Kim JH, Joon BU, Ryu HJ. Clinical effectiveness of a high-intensity focused ultrasound in skin lifting. *Med Lasers.* 2014;3(2):55-58.
5. Suh DH, Choi JH, Lee SJ, Jeong KH, Song KY, Shin MK. Comparative histometric analysis of the effects of high-intensity focused ultrasound and radiofrequency on skin. *J Cosmet Laser Ther.* 2015;17(5): 230-236.